

# **THE EFFECT OF AIR FRESHENER EXPOSURE AT AN EARLY AGE ON ALVEOLAR HISTOLOGY OF WHITE RAT (*RATTUS NORVEGICUS*)**

**Yuningtyaswari<sup>a</sup>, Erlina Widyastuti<sup>b</sup>**

<sup>a</sup>Departement of Histology & Biology, School of Medicine, Faculty of Medicine & Health Science, Universitas Muhammadiyah Yogyakarta; Jalan Lingkar Selatan, Tamantirto, Kasihan, Bantul DIY, Indonesia 55183

<sup>b</sup>Student of School of Medicine, Faculty of Medicine & Health Science, Universitas Muhammadiyah Yogyakarta; Jalan Lingkar Selatan, Tamantirto, Kasihan, Bantul DIY, Indonesia 55183

Corresponding author. Tel.: +628122796167; fax: +62274387658.

E-mail address: [yuningtyas@umy.ac.id](mailto:yuningtyas@umy.ac.id)

# INTRODUCTION

- Air freshener at this time familer used to reduce unpleasant odors in an enclosed space.
- Gel air freshener and spray air fresehener more often used in society.
- In general, people do not be aware of the danger behind the comfortable and fresh sensation emitted by air freshener.



- Air freshener contains various volatile organic compound include formaldehyde and phthalates. Formaldehyde is a VOC that is very dangerous for pulmonary (SCHER, 2006).
- Formaldehyde can cause inflammation and lead to oxidative stress in pulmonary tissue (Lino, A.,*et al*, 2011).
- Di- (2-ethylhexyl) phthalate (DEHP) is a compound derived from phthalates that can cause inflammation in the pulmonary alveoli due to stress oksidatif (Abdel-gawad, S.K. and Atia, T. 2013).
- Gel air freshener contained more formaldehyde, whereas spray air freshener contained more chemical substances DEHP (SCHER, 2006).

The research aimed to assess the effect of gel and spray air freshener exposure on alveolar histology of *Rattus norvegicus* at an early age

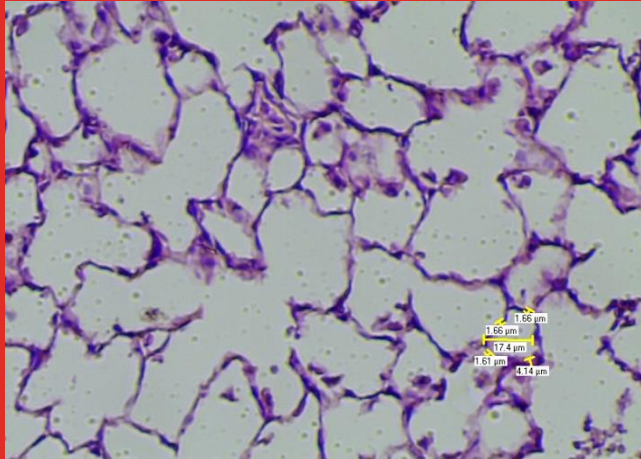


# MATERIAL AND METHODS

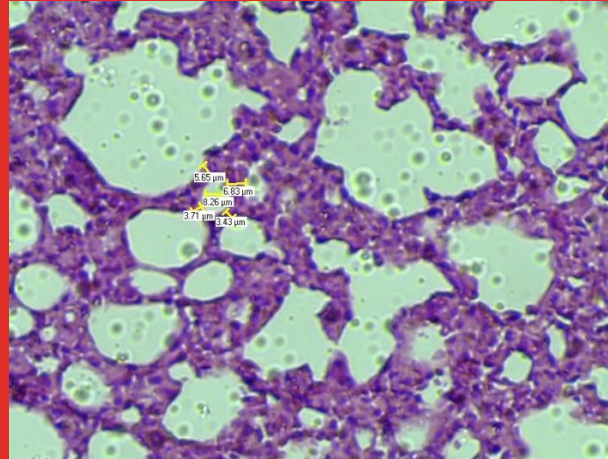
- 30 male white rat (*Rattus norvegicus*) Spraque Dawley strain, 7 days old at the beginning of treatment. These subject were divided into 10 rats for each group gel (P1), spray (P2), and control (K).
- Group P1 was treated exposures gel air freshener, brand X.
- Group P2 was treated exposures spray air freshener, brand X.
- The control group (K) was not given any treatment.
- The giving treatment starts at a dose of 15 minutes, 2 times a day. Exposure dose was increased to 15 minutes per exposure per week, to reach a final dose of 4.5 hours (at 67 days of treatment).

- On day 68, subjects were sacrificed, followed by pulmonary dissection, and made preparations pulmonary histology.
- Pulmonary histology preparations made by the method of paraffin blocks, with Hematoxylin eosin staining techniques. Preparations pulmonary histology observed with a light microscope at a magnification of 10x10.
- The histologic features were observed pulmonary alveolar septum thickness, diameter of the alveoli and number of inflammatory cells (lymphocytes, PMN, plasma, eosinophils, and histiocytes).
- Data is analyzed by Kruskal-Wallis method, followed by Mann Whitney test.

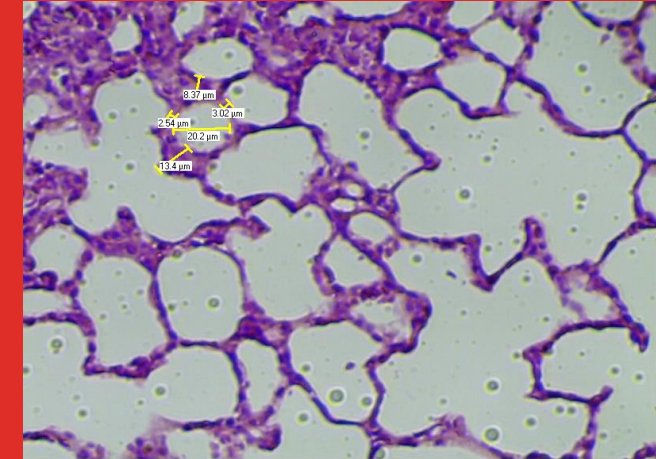
# RESULT AND DISCUSSION



a) Alveolar histology of Control group (K) (HE, 10x10)



(b) Alveolar histology of Gel group (P1) (HE, 10x10)



(c) Alveolar histology of Spray group (P2) (HE, 10x10)

Figure 1 : alveolar histology of subject

# RESULT AND DISCUSSION

- This study shows that the effects of exposure to the gel air freshener septum thickness interalveolaris worse than freshener spray.
- Freshener gels, contain more formaldehyde than the liquid preparation / spray (SCHER, 2006).
- Mechanisms interalveolaris septal thickening gel group (P1) caused by formaldehyde inhalation causes edema in the tissue around the pulmonary alveoli due to inflammation that occurs through the stimulation of tachykinin NK1 receptors and oxidative stress mechanisms.

- In the spray group (P2), interalveolaris septal thickening caused by di- (2-ethylhexyl) phthalate (DEHP) phthalate derivatives which are compounds that are found in liquid / spray air freshener.
- Compounds that settles in pulmonary DEHP can act as a partial agonist of the Peroxisome Proliferator-Activated Receptor- $\gamma$  (PPAR $\gamma$ ) and stimulate oxidative stress. Both of these mechanisms cause edema septum interalveolaris therefore inflammatory process (Kocbach, A. 2013).
- Septal thickening interalveolaris also affected by the process of atelectasis (lung development is not perfect due to alveolar collapse).
- In this study, atelectasis caused by lung extrinsic pressure increased due to scar tissue (fibrosis) of the septum interalveolaris (Price, S and Wilson, L. M., 2006). As a result of the collapse of the alveoli, the septum adjacent interalveolaris will blend and conjured images of a thickened septum.



- The results showed that the average diameter of alveolar spray group > control group > group gel.
- Alveolar diameter size changes in the gel group, influenced by the effects of formaldehyde in air freshener gels which causes edema and atelectasis.
- Both processes spur interalveolaris septal thickening, so that will compress the size of the alveoli (Mohamed, A. M. T., et al , 2012). This makes the size of the diameter of the alveoli become increasingly narrow.
- This study has shown that alveolar diameter in the spray group (P2), has the widest measure than other groups. This happens because of their exposure to DEHP compound that causes increased production of free radicals (Reactive Oxygen Substance (ROS)) (You,H., et al., 2014).
- Free radicals can damage cell membranes and protein constituent spur proteolytic degradation of elastin by elastase. Resulting in a drop forming septum interalveolaris woven from fibers elastin and reticuline (Anindyajati, EA., 2007).

- Acute inflammatory cells, appears to dominate the control group. Mild acute inflammation that occurs in the control group, may be caused by inhalation of ammonia substances in animal urine test and not caused by exposure freshener.
- The mechanism of injury occurs when ammonia gas ( $\text{NH}_3$ ) reacts with tissue fluids to form a highly alkaline solution, called ammonium hydroxide (Permata, G. S., 2011).
- Acute inflammatory cell infiltration in the gel group (P1) and spray (P2) is not only caused by the substance of ammonia, but also because their mechanism of acute exacerbation of chronic inflammation due to exposure freshener.
- Acute exacerbation of chronic inflammatory process causing no significant differences between groups of acute inflammatory cells, gel and spray. However, the number of acute inflammatory cells and spray gel group more and has had a statistically significant difference with the control group.

- Gel group (P1) and spray (P2) is dominated by chronic inflammatory cells that should be marked by infiltration of lymphocytes, macrophages, and plasma cells are prominent.
- However, in this study the cell histiocytes (macrophages) and spray gel group has an average amount of at least compared with other inflammatory cells.
- The condition occurs as a result of this study using formalin 10% (instead of formalin buffer) for organ fixation process. So that the cells histiocytes become less visible and increase their possibility of cells that are not counted.

# CONCLUSION

- Exposure air freshener adversely affect alveolar histology in rats (*Rattus norvegicus*) at early age, through observation alveolare septum thickness, alveolar diameter, and the calculation of the number of inflammatory cells. This study also shows that gel air freshener exposure has a worse effect than the spray air freshener.

# CONCLUSION

- Abdel-gawad, S.K. & Atia, T. 2013. Histological and Ultrastructure Changes Induced by Di {2-ethylhexyl} Phthalate (DEHP) in the Alveolar Tissue of Adult Albino Rats and the Possibility of Recovery. *J Cell Science & Therapy (Online)*, Vol. 4, No. 141, <http://omicsonline.org/histological-and-ultrastructure-changes-induced-by-di-2-ethylhexyl-ftalat-dehp-in-the-alveolar-tissue-of-albino-rats-2157-7013.1000141.pdf>, Last accessed 6 April 2014)
- 
- Anindyajati, EA. 2007. *Pengaruh Asap Pelelehan Lilin Batik (Malam) Terhadap Struktur Histologis Trakea dan Alveoli Pulmo, Jumlah Eritrosit Serta Kadar Hemoglobin Mencit (Mus musculus l.)*. Unpublished Thesis. Surakarta : Universitas Sebelas Maret, Indonesia
- 
- Junqueira, C.J., & Carneiro, J. 2009. *Basic Histology (ed. 11)*. USA: The Mcgraw-hill Co. pp. 335-355
- 
- Kocbach, A. 2013. Pulmonary Phthalate Exposure and Asthma – Is PPAR a Plausible Mechanistic Link?. *EXCLI Journal (Online)*, Jilid 12, [http://www.excli.de/vol12/Kocbach\\_Bolling\\_20082013\\_proof.pdf](http://www.excli.de/vol12/Kocbach_Bolling_20082013_proof.pdf), Last accessed 1 April 2014)
- 
- Lino, Adriana, Correa, Matheus & Carolina, Ana., 2011. Formaldehyde Induces Lung Inflammation by an Oxidant and Antioxidant Enzymes Mediated Mechanism in the Lung Tissue. *Toxicology Letters (Online)*, Vol. 207, No.3, <http://www.sciencedirect.com/science/article/pii/S0378427411015542>, Last accessed 6 April 2014)
-

- Mohamed, A. M. T., El-Ashtokhy, M., Ahmed, H., & Ibrahim, O. 2012. Anatomical and Histological Effects of Formaldehyde Inhalation on the Lung of Albino Rat. *Journal of American Science*, (Online), Vol 8, No.9, [http://www.jofamericanscience.org/journals/amsci/am0809/057\\_10494am0809\\_395\\_404.pdf](http://www.jofamericanscience.org/journals/amsci/am0809/057_10494am0809_395_404.pdf), Last accessed 11 April 2014).
- 
- Permata, G. S., 2011. *Gambaran fungsi Paru Pekerja Bagian Produksi Lateks yang Terpajan Amoniak Di PT Socfindo Kebun Aek Pamienke Kabupaten Labuhan Batu Utara Tahun 2010*. Unpublished Thesis. Medan : Universitas Sumatra Utara, Indonesia
- 
- Price S. A., Wilson L. M. 2006. *Patofisiologi – Konsep Klinis Proses-Proses Penyakit Edisi 6*. Jakarta : EGC
- 
- Rahayu, N. 2008. *Buku Ajar Respirologi Anak Edisi Pertama*. Jakarta: Badan Penerbit IDAI. pp. 8-10.
- 
- Scientific Committee on Health and Environmental Risks (SCHER), 2006. Emission of Chemicals by Air Fresheners Test on 74 Consumer Products Sold in Europe. *European Commission* (Online), Vol. 1, No. 19, [http://ec.europa.eu/health/ph\\_risk/committees/04\\_scher/docs/scher\\_o\\_026.pdf](http://ec.europa.eu/health/ph_risk/committees/04_scher/docs/scher_o_026.pdf), Last accessed 9 Februari 2014
- 
- Viktor, 2008. *Bahaya Pengharum Ruangan Buat Anak*. Medan : Dinas Kesehatan Sumatera Barat (Online), <http://www.repository.usu.ac.id/bitstream/123456789/21023/5/Chapter%201.pdf>, Last accessed on 1 April 2014).
- 
- You, H., Chen, Mao, Li, Bing. 2014. The Adjuvant Effect Induced by Di-(2-ethylhexyl) Phthalate (DEHP) is Mediated Through Oxidative Stress in a Mouse Model of Asthma. *Food and Chemical Toxicology* (Online), vol. 71, <http://www.sciencedirect.com/science/article/pii/S0278691514002877>, Last accessed on 6 Oktober 2014